

Tools RG
Know how to show how

You Can Personalise This Text Your Clinic Name Here

Your address

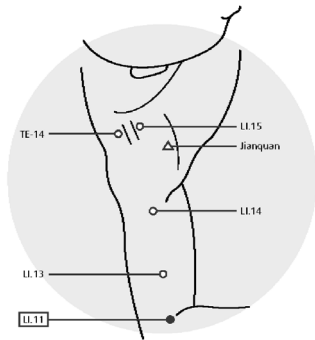
Your Telephone/Fax/Email/Website

You can have more than one header

Provided for : Patient's Name

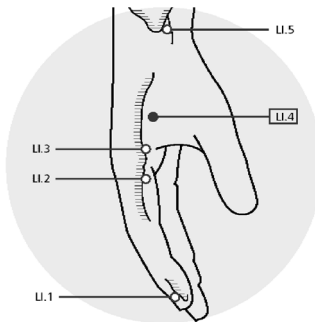
Acupuncture

Provided by : Your Name



- ~ Add your own pictures and text
- ~ Edit and save existing text and pictures
- ~ Flip the pictures to show either side
- ~ Change the size of the text - ideal for the visually impaired
- ~ Print 1, 2, 5 or 10 items per page
- ~ Print a personal training diary and/or miniature summary for your records
- ~ Text can be printed in 16 different languages at no additional charge
- ~ Store often used protocols for later use

© Chris Norris



Large Intestine 4

Location: On the dorsum of the hand, between the first and second metacarpal bones, within the adductor pollicis muscle. The point is at the midpoint of the second metacarpal bone, close to its radial border.

Needling: Perpendicular insertion 0.5 - 1 cun.

Caution: Strong manipulation of this point is contraindicated in pregnancy as it is said to promote childbirth.

© Chris Norris

Note: (i) The point lies on a line bisecting the angle formed by the 1st and 2nd metacarpals when the thumb is fully abducted (ii) when the thumb is fully adducted, the point lies at the highest point of the muscle bulge (dorsal interosseous muscle), (iii) The therapist places the distal phalanx of their own thumb onto the patients thumb web and points their thumb towards the patients metacarpal shaft. The point lies at the tip of the therapists thumb.

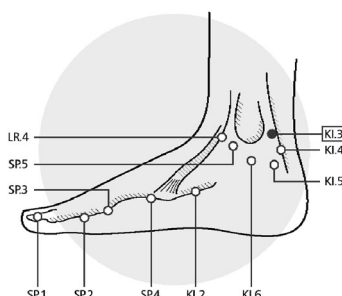
Uses: One of the most widely used acupuncture points, LI.4 is a heavenly star point. It is the source point of the large intestine channel, and command point for the face and mouth. Used for head and neck symptoms, headache and facial pain.

Kidney 3

Location: In the centre of the depression between the apex of the medial malleolus and the Achilles tendon (Kager's triangle).

Needling: Perpendicular insertion 0.5 - 1 cun.

Note: This point is approximately opposite BL.60, which is similarly related to the apex of the lateral malleolus. However, as the medial malleolus is higher than the lateral, the two points are not directly opposite.



© Chris Norris

Uses: (i) Achilles tendon pain. (ii) Often used point to treat headaches. (iii) Source point of the kidney channel.

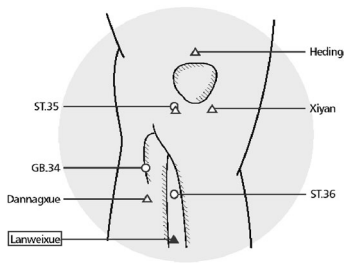
Lanweixue (EX-LE 7)

Location: Approximately 2 cun distal to ST.36 (5 cun distal to ST.35, the lateral eye of the knee) on the right leg only.

Needling: Perpendicular insertion 1 - 1.5 cun.

Note: Locate at the point of maximum tenderness.

Uses: Traditionally used to treat pain from appendicitis. Claimed to be diagnostic in that tenderness is only seen when the appendix is inflamed.



© Chris Norris